

# Minimally Invasive Oblique Lumbar Interbody Fusion for the Treatment of Multilevel Degenerative Disc Disease: Review of the Surgical Technique Based on a Case Report

## Fusão Ântero-Lateral Minimamente Invasiva da Coluna Lombar no Tratamento da Discopatia Degenerativa Multinível: Revisão da Técnica Cirúrgica a Propósito de um Caso Clínico

Gonçalo Lavareda<sup>1</sup>, Manuel Tavares de Matos<sup>2\*</sup>

### \* Corresponding Author/Autor Correspondente:

Manuel Tavares de Matos [spine.tm@gmail.com]  
R. Abílio Mendes 12, 1500-458 Lisboa, Portugal

### Abstract

The treatment of multilevel lumbar disc disease is not consensual and represents a major challenge for spine surgeons.

The minimally invasive oblique lumbar interbody fusion (MI-OLIF) allows an anatomic dissection of the lateral abdominal wall until anterior column of lumbar spine. It is an anterior to Psoas approach that avoids lumbar plexus and muscle lesion which conduct to a well tolerated postoperative period, with less pain, early discharge, and fast return to active life.

The authors present a patient with chronic low back pain and neurological claudication, secondary to degenerative lumbar disc disease (L2-L5) treated with L2-L5 MI-OLIF. With low surgical aggression, the coronal and sagittal imbalance were corrected and lumbar and foraminal stenosis were indirectly decompressed.

The patient ambulated at first day postoperative and was discharge at day three. At six months postoperative, fusion was confirmed, and pain and functionality were significantly increased. No complications were reported.

**Keywords:** Intervertebral Disc Degeneration/surgery; Lumbar Vertebrae; Minimally Invasive Surgical Procedures; Spinal Fusion

### Resumo

O tratamento da discopatia lombar multinível, não é consensual e representa um grande desafio para os cirurgiões.

A técnica *Minimally Invasive Spine Surgery - Oblique Lumbar Interbody Fusion (MISS OLIF)*, permite uma dissecação romba da parede abdominal lateral até à coluna vertebral. A via de acesso é anterior ao Psoas, evitando-se a lesão muscular e do plexo lombar, permitindo um pós-operatório bem tolerado, levante e alta precoce e um rápido retorno à vida ativa.

Os autores apresentam um caso de uma paciente com queixas de lombalgia e claudicação neurológica, secundária a discopatia degenerativa da coluna lombar (L2-L5), operada por via *OLIF-MI* tendo-se obtido uma boa correção no plano sagital e coronal, assim como a descompressão indireta da estenose lombar e foraminal.

1. Serviço de Ortopedia e Traumatologia, Hospital Ortopédico Sant'Iago do Outão; Colaborador do Serviço de Ortopedia do Hospital Lusíadas Lisboa, Lisboa, Portugal.  
2. Consultor Graduado de Ortopedia. Serviço de Ortopedia e Traumatologia, Hospital Lusíadas Lisboa, Lisboa, Portugal.

**Received/Recebido:** 22-02-2021 - **Accepted/Aceite:** 11-03-2021 - **Published/Publicado:** 31-03-2021

© Author(s) (or their employer(s)) and Lusíadas Scientific Journal 2021. Re-use permitted under CC BY-NC. No commercial re-use. © Autor (es) (ou seu (s) empregador (es)) e Lusíadas Scientific Journal 2021. Reutilização permitida de acordo com CC BY-NC. Nenhuma reutilização comercial.

A doente efetuou levante no primeiro dia de pós-operatório e teve alta hospitalar ao terceiro. Aos seis meses pós-operatórios, a fusão lombar estava estabelecida nos três níveis discais, com melhoria da dor e funcionalidade. Não foram reportadas complicações.

**Palavras-chave:** Degeneração do Disco Intervertebral/cirurgia; Fusão Vertebral; Procedimentos Cirúrgicos Minimamente Invasivos; Vértebras Lombares

## Introduction

The treatment of multilevel lumbar disc disease, especially the ideal approach, is not consensual and represents a major challenge for spine surgeons.

The anterolateral approach to the lumbar spine, by comparison with the posterior or posterolateral approach, allows for a more comprehensive exposure of the disc space and the introduction of a larger intersomatic cage, either neutral or promoting lordosis. By this way, there is a more physiological and homogeneous load distribution over the anterior column, reducing the risk of adjacent disc disease, increasing the possibility of fusion and restore the physiological lumbar lordosis.<sup>1</sup>

The minimally invasive oblique interbody fusion (MI-OLIF) is a less invasive approach, once the utilization of expandable retractors allows a limited and anatomic dissection of the lateral abdominal wall until the retroperitoneal space, where the anterior column of lumbar spine is reached. The posterior muscular plane (erector spinae muscles) is spared, the canal and the nerve roots are not manipulated, and hemorrhagic loss is minimal. This allows a generally well tolerated postoperative period, with less pain, fast recovery, early discharge, and a quick return to a normal active life.<sup>1</sup>

With this technique the lumbar and foraminal stenosis are indirectly decompressed and the lumbar lordosis could be restored, with a better anterior support, correcting sagittal and coronal plan deformities.

When mastered, MI-OLIF it is a relatively safe and highly effective technique for minimally invasive lumbar fusion, with good clinical and radiograph outcomes.

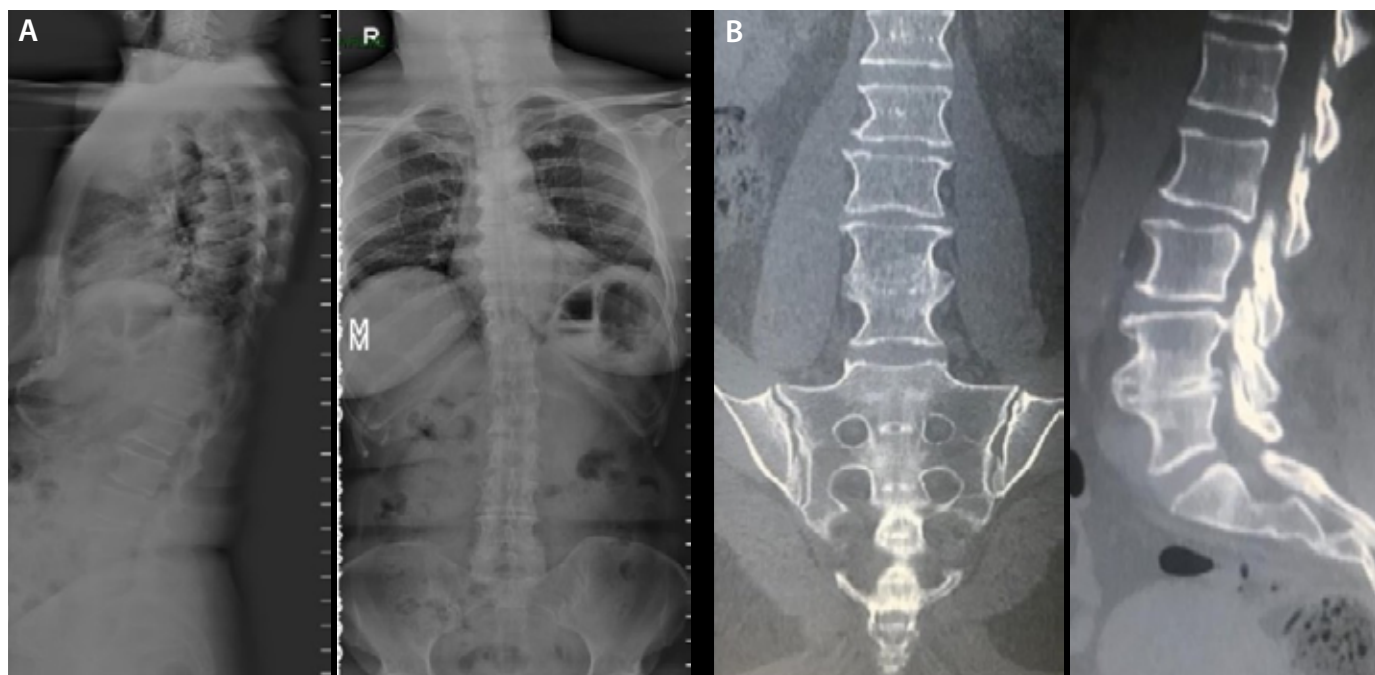
## Case Report

A 69-year-old female presented to our department with chronic low back pain and neurogenic claudication with left radicular pain at L5 nerve root territory, worsening during the last few months. These symptoms were affecting her social life and daily activities. No fever or weight loss was found.

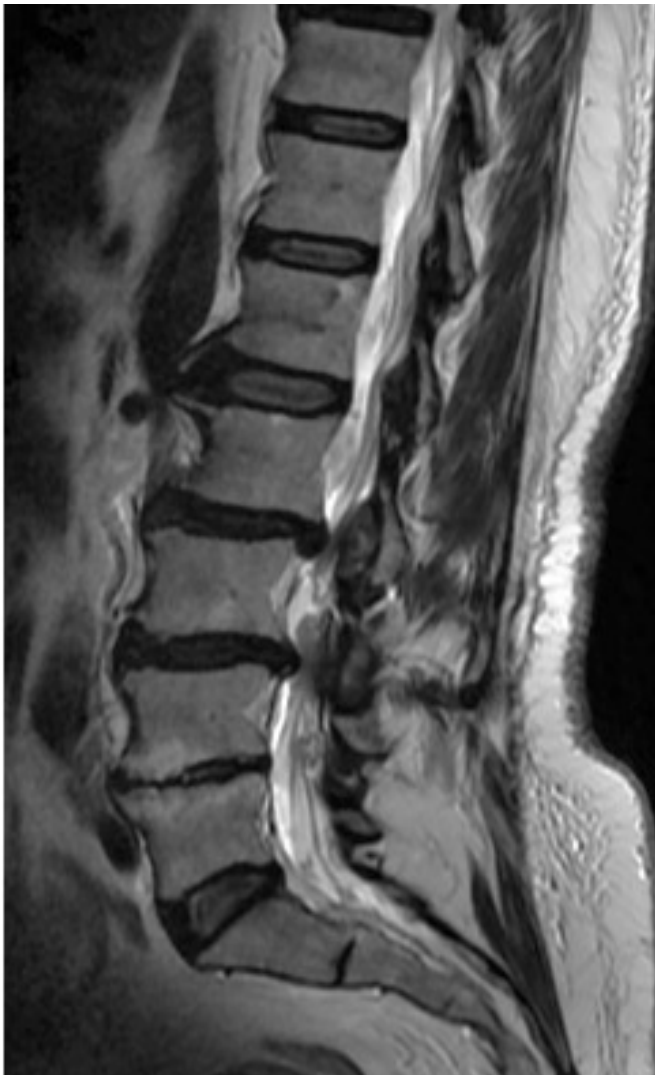Her past medical history revealed high blood pressure. No history of abdominal surgery, chemotherapy or radiotherapy or abdomino-pelvic infection was found.

At the clinical examination, left Bragard and Lasegue tests were positive. The patient had no motor or sensitive deficit and the osteotendinous reflexes were normal. Right lower limb examination was normal and there were no signs of lower limb venous or arterial disease. Hip and knee examination was normal. She reported a left leg pain Visual Analogue Scale 7, axial pain Visual Analogue Scale 4, Oswestry Disability Index 36%, Body Mass Index 27 kg/m<sup>2</sup> (162 cm; 70 kg).

Lumbar loaded radiograph showed a multilevel degenerative disc disease with L4-L5 ankylosis and a loss of normal lumbar lordosis, that was compensated by dorsal rectification and kyphosis loss (Fig. 1A).



**Figure 1.** (A) Lateral and anteroposterior longstanding radiograph; (B) CT with L4-L5 disk collapse and ankylosis.



**Figure 2.** Preoperative lateral MRI.

The computed tomography (CT) scan confirmed a multilevel degenerative disc disease, with disc protrusions, especially at L2-L3 and L4-L5. At L4-L5 vertebral body was evident an ankylosis with a notorious anterior osteophyte (Fig. 1B).

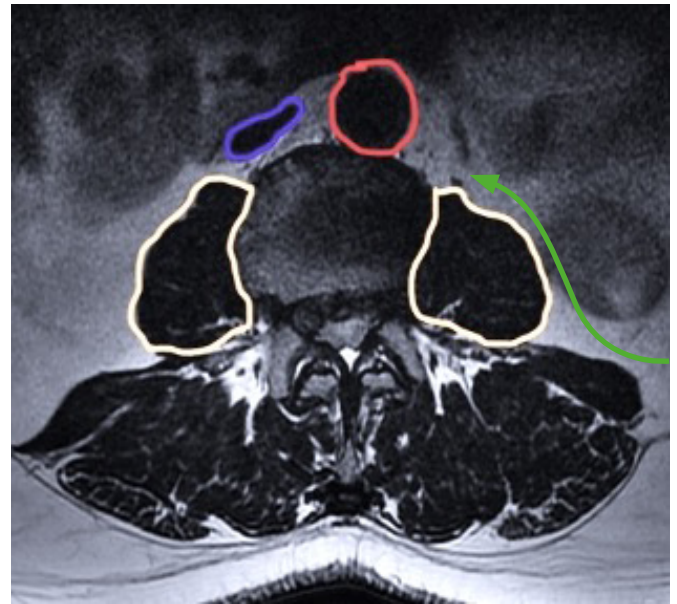
Magnetic resonance imaging (MRI) demonstrated a marked L2-L3, L3-L4 and L4-L5 degenerative disc disease, with diffuse posterior disc prominence conditioning lumbar and foraminal stenosis (Fig. 2). There could be also seen articular facet arthrosis and flavum ligament hypertrophy contributing for stenosis. At L4-L5 level it was evident Modic 2 degenerative changes (Fig. 2).

An anterior enlargement of L1-L2 and L5-S1 discs was noted. This happens as a compensatory mechanism to segmental lordosis loss.<sup>2</sup>

Pelvic parameters: sacral slope (SS) 35°; pelvic incidence (PI) 58°; pelvic tilt (PT) 23°; lumbar lordosis (LL) 54°.

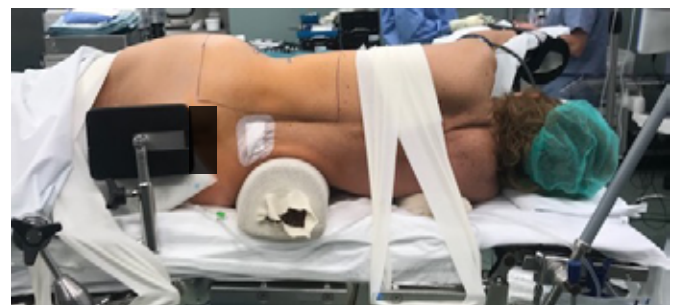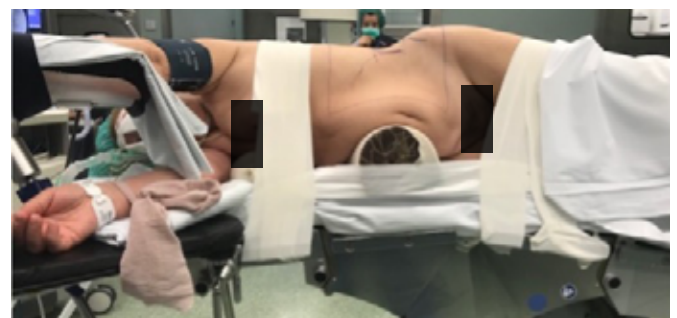The patient was proposed for a L2-L5 spine fusion through a combined anterolateral approach supplemented with percutaneous unipedicular fixation.

A left approach was preferred since it allows the surgeon to avoid cava vein. As preoperative planning the authors use MRI



**Red:** Aorta | **Blue:** Cava Vein | **Yellow:** Psoas | **Green:** OLIF corridor

**Figure 3.** L2-L3 corridor approach (Axial T2 MRI).

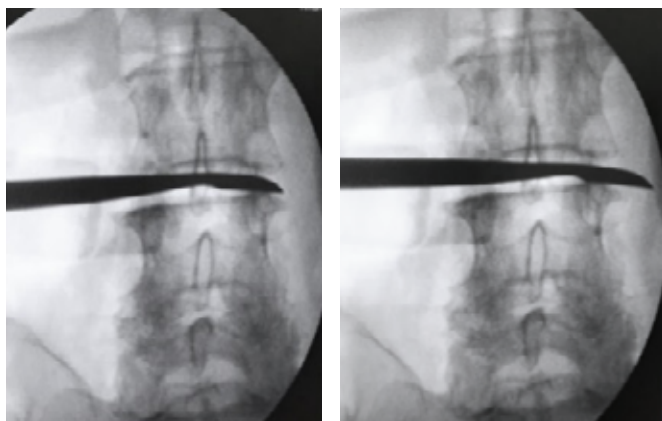


**Figure 4.** Patient positioning.

to identify the vascular and abdominal structures, eventually with 3D FOV volumetric sequence between L1 and S1 in T2. If any doubts emerge or abnormalities were identified, a lumbar CT angiography is requested. It is important to consider the volume of psoas muscle or far lateral left iliac vein trajectory that could limit the lateral corridor (Fig. 3).

The patient was positioned in right lateral decubitus with left hip slightly flexed (diminishing psoas muscle tension) and with a right flank support to increase costal rib-iliac crest distance (Fig. 4).<sup>3</sup> For each level, the surgeon needs to ensure that an ideal lateral and AP fluoroscopy view could be obtained intraoperative. The procedure was made using a minimally invasive spine surgery (MISS) retroperitoneal approach, with Synframe retractor.





**Figure 5.** Intraoperative fluoroscopic control of contralateral annulus fibrosus release.

A unique oblique incision, slightly anterior to the left iliac crest, was planned with fluoroscopic control. A classic subcutaneous tissue dissection was performed with caution to avoid lateral subcutaneous nerves. The external and internal abdominal muscles were opened along with their fibers. At this step, careful should be taken with iliohipogastric and ilioinguinal nerves that cross abdominal wall at this level, along with muscle fibers. After identification of the peritoneal sac, the surgeon directed the approach to the posterior muscle wall, between peritoneum and the posterior abdominal wall, until the psoas muscle was found.

At this stage, the approach was medialized, working between the aorta and anterior psoas limit, where the disc space was seen, moving away the psoas as necessary and, avoiding injury to the emerging nerve roots.

Extremely careful should be taken concerning the iliolumbar vein that could be found at L4L5 level. Left iliolumbar veins tend to have a more distal origin, lower width, and more branches.<sup>4</sup> Care is taking to stay near the disc during access, avoiding segmental vessels.

Each disk level has different structures at risk. The ureter can appear at surgical field at L1-L2 level (identified by ureteral peristalsis) as well as the kidney.

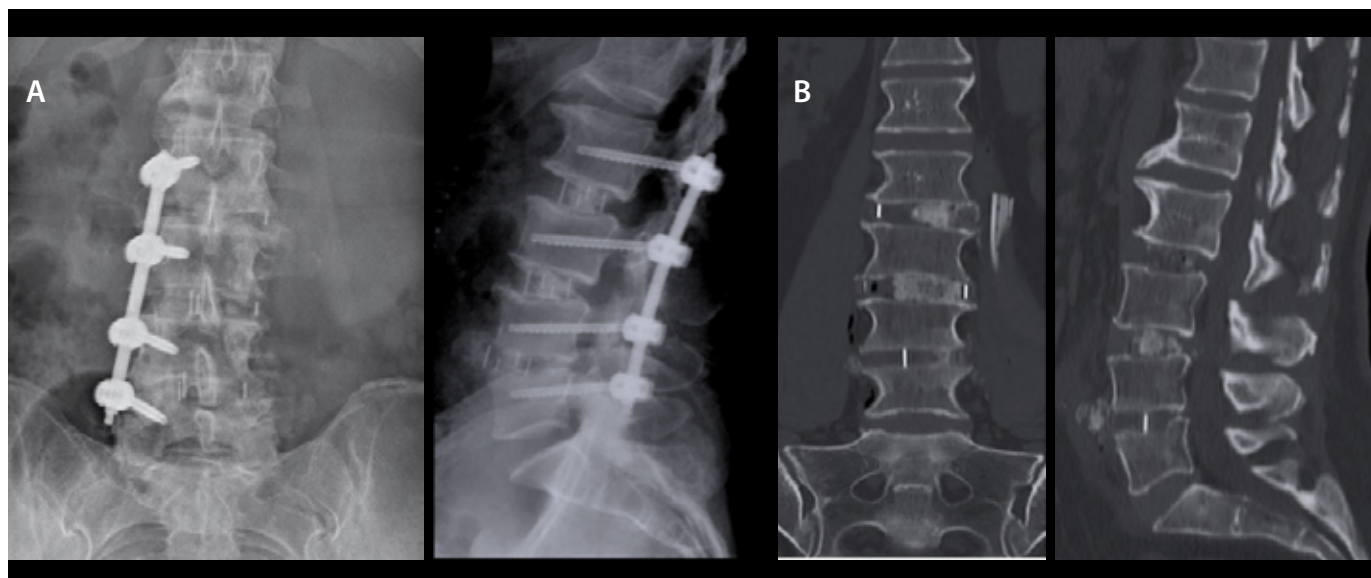
After identifying the disc space and the ALL the surgeon confirmed the correct level with fluoroscopy. The annulus fibrosus is cleared of soft tissues under Synframe blade. A rectangular window incision, as large as possible, is made on the lateral aspect of annulus fibrosus to access the disk space.

Discectomy was performed and meticulous preparation of the end plates, under fluoroscopic control, was made using spacers progressively, until the desire height is obtained. The release of the disc and annulus at both sides was made using a Cobb elevator (Fig. 5). This is crucial to obtain a greater disc space distraction.

Since oblique lumbar interbody fusion (OLIF) approach avoids crossing the psoas muscle, preventing lumbar plexus lesion, usually neuromonitoring it is not necessary.

A critical step is the implant insertion as it initially follows an oblique and posterior direction, that must be corrected during insertion in order to avoid the lesion of the contralateral foramen or even vertebral canal. If to anterior can damage the cava vein. The adequate size of the spacer was confirmed with fluoroscopy as it needs to be large enough to be supported by the lateral cortical bone of the vertebra. A PEEK spacer with 8° of lordosis, augmented with synthetic bone graft was inserted, strictly perpendicular, under fluoroscopic control. A Jackson Pratt drain was left at surgery site and the wound was closed in layers. There was an estimated blood loss of 150 mL. The construction was complemented with right percutaneous unilateral transpedicular screw fixation at the same levels (Fig. 6A).

At day 1 postoperative the drain was removed, and the patient was encouraged to ambulate. No complications were registered, and the patient was discharged from hospital at day three postoperative.



**Figure 6.** Postoperative radiograph (A) and CT scan (B).

## Discussion

Spine surgery for elderly population is increasing as the population ages. Complications are not rare and morbidity reduction in spine fusion is an endpoint that may be achieved with less invasive techniques. The oblique approach (OLIF) has become an increasingly popular approach for achieving interbody fusion, and promising results have been reported.<sup>3</sup> This technique combines the benefits of minimally invasive approaches with less complications traditionally associated with transposas approach.<sup>3,5</sup>

In comparison to posterior approaches the minimally invasive anterolateral approach to the lumbar spine is associated with less neurologic risk (dural tears or radicular lesions), less blood loss, no posterior arch, muscle or tension band lesion and fast postoperative recovery.

Indications for OLIF includes lumbar degenerative scoliosis, foraminal stenosis causing radiculopathy, lumbar stenosis causing neurogenic claudication, degenerative lumbar spinal deformity with symptomatic spondylolisthesis or spondylolysis grade 1 or 2. This oblique route allows deformity correction at multiple segmental levels (L1-S1) from the same patient positioning, with possibility for direct release of the anterior longitudinal ligament (ALL) acquiring the necessary lordosis, being in some cases an alternative to pedicle subtraction osteotomy (PSO). It permits a larger graft insertion and homogeneous distraction of vertebrae, which allows the correction of the coronal and sagittal deformity. In addition, the anterior cage position corresponds to the most vascularized region of the vertebral body, stimulating fusion.<sup>3,5</sup>

With anterior approaches the neural decompression is achieved indirectly opening the foramen and stretching the LVCP and flavum ligament. The oblique route provides access to contralateral side efficient release and wide discectomy.<sup>6</sup>

Besides that, since it is an approach anterior to psoas muscle, there is less muscular and neurologic lesion risk. Minimal or any mobilization of great vessels is necessary, and it allows direct visualization of anterior epidural space.

This technique must be carefully considered in patients with previous history of multiple abdominal surgery or revision of an anterior spine approach. These circumstances increase the risk of vascular or urologic complications since retroperitoneal release proves challenging.<sup>3,5</sup>

In this case, the patient suffered from a multilevel disc disease (L2-L5) that lead to changes in the alignment and relationship between lumbar vertebrae. The lumbar lordosis was decreased, and it was possible to see some adaptative changes like an anterior opening of L1-L2 and L5-S1 discs (lateral radiograph on Fig. 1A) and an increased posterior pelvis tilt of 23°. These compensatory mechanisms allow the patient, with effort, to maintain the head above the pelvis, a lumbar lordosis of 54° and a balanced but compensated sagittal alignment.<sup>2</sup>

**Table 1.** Pelvic parameters

(PT= 0,37 PI-7; LL (L1-S1) = 0,54 x PI + 27,6)<sup>4</sup>

Pelvic Parameters	PI	SS	PT	LL
Theoretical Values	58	43,54	14,46	58,92
Preoperative	58	35	23	54
Postoperative	58	40	18	58

Clinical and radiograph results were evaluated preoperative and at 6 months postoperative.

The VAS was improved, back pain from 4 to 0, and leg pain from 7 to 0. The ODI improved from 36% to 8%.

The most postoperative significant complaint was stiffness at extreme lumbar flexion. The patient was satisfied with the procedure and would choose to go on surgical treatment again.

Particular attention was paid to L4-L5 collapsed level. It was possible to carefully retract anteriorly the major vessels, remove the large anterior osteophyte, release the lateral structures, and open again the L4-L5 disk level. A lordotic cage was then inserted.

With the improvement height at the three intersomatic spaces, the authors were able to achieve an increase in sacral slope and lumbar lordosis, as well as a consequent decrease in pelvic tilt. The postoperative sagittal parameters were closer to what would be expected (pelvic incidence of 58°). Bone ingrowth and fusion were confirmed at six months follow up.

This is a case report with its inherent limitations.

## Conclusion

In conclusion, the minimally invasive antero-lateral approach of the lumbar spine can be used to treat adult lumbar degenerative disease with a favourable improvement in clinical and radiograph outcomes. It spares the posterior spinal muscles and posterior vertebral arches and limits iatrogenic lesions to dural sac content or nerve roots. The instrumentation restores interbody space height, foraminal diameter, segmental lordosis and corrects coronal malalignment with an indirect decompression of foramina and lumbar canal.

With this MISS procedure the patient had low postoperative pain, a soon return back home and a good clinical and radiograph outcome. No complications were registered.

## Responsabilidades Éticas

**Conflitos de Interesse:** Os autores declaram a inexistência de conflitos de interesse na realização do presente trabalho.

**Fontes de Financiamento:** Não existiram fontes externas de financiamento para a realização deste artigo.

**Confidencialidade dos Dados:** Os autores declaram ter seguido os protocolos da sua instituição acerca da publicação dos dados de doentes.

**Consentimento:** Consentimento do doente para publicação obtido.

**Proveniência e Revisão por Pares:** Não comissionado; revisão externa por pares.

## Ethical Disclosures

**Conflicts of Interest:** The authors have no conflicts of interest to declare.

**Financing Support:** This work has not received any contribution, grant or scholarship.

**Confidentiality of Data:** The authors declare that they have followed the protocols of their work center on the publication of data from patients.

**Patient Consent:** Consent for publication was obtained.

**Provenance and Peer Review:** Not commissioned; externally peer reviewed.

**ORCID iD:** Manuel Tavares de Matos <https://orcid.org/0000-0002-8483-500X>

## References

1. Joob B, Wiwanitkit V. Multilevel Anterior Lumbar Interbody Fusion Combined with Posterior Stabilization in Lumbar Disc Disease - Prospective Analysis of Clinical and Functional Outcomes. *Rev Bras Ortop.* 2020;55:653. doi: 10.1055/s-0040-1701283.
2. Le Huec JC, Thompson W, Mohsinaly Y, Barrey C, Faundez A. Sagittal balance of the spine. *Eur Spine J.* 2019;28:1889-905. doi: 10.1007/s00586-019-06083-1. Erratum in: *Eur Spine J.* 2019 Aug 26.
3. Sumihisa O. Oblique Lateral Interbody Fusion (OLIF): Indications and techniques - *Oper Techniq Orthop.* 2017;27:223-30.
4. Davis M, Jenkins S, Bordes S, Iwanaga J, Loukas M, Uribe J, et al. Iliolumbar Vein: Anatomy and Surgical Importance During Lateral Transposas and Oblique Approaches to Lumbar Spine. *World Neurosurg.* 2019;128:e768-e772. doi: 10.1016/j.wneu.2019.04.252.
5. Mobbs RJ, Phan K, Malham G, Seex K, Rao PJ. Lumbar interbody fusion: techniques, indications and comparison of interbody fusion options including PLIF, TLIF, MI-TLIF, OLIF/ATP, LLIF and ALIF. *J Spine Surg.* 2015;1:2-18. doi: 10.3978/j.issn.2414-469X.2015.10.05.
6. Sato J, Ohtori S, Orita S, Yamauchi K, Eguchi Y, Ochiai N, et al. Radiographic evaluation of indirect decompression of mini-open anterior retroperitoneal lumbar interbody fusion: oblique lateral interbody fusion for degenerated lumbar spondylolisthesis. *Eur Spine J.* 2017;26:671-8. doi: 10.1007/s00586-015-4170-0.