

Pneumocephalus: An Infrequent Cause of Altered State of Consciousness

Pneumoencéfalo: Uma Causa Pouco Frequente de Alteração do Estado de Consciência

Filipa Taborda^{1*}, Beatriz Fernandes¹, Maria João Lobão²

*** Corresponding Author/Autor Correspondente:**

Filipa Taborda [filipataborda92@gmail.com]

Av. Brigadeiro Victor Novais Gonçalves, 2755-009 Alcabideche, Portugal

Palavras-chave: Perturbações da Consciência; Pneumocefalia

Keywords: Consciousness Disorders; Pneumocephalus

A 47-year-old man is admitted to the Emergency Room with head trauma after falling from his own height. He had no history of relevant medical conditions, except for previous episodes of acute ethanolism. Upon admission he presented a Glasgow Coma Scale score of 11 (E3V3M5) and otorrhagia, without evidence of focal neurologic deficits, namely anisocoria. Blood pressure was 136/83 mmHg with a heart rate of 43

beats per minute, with no known usual drugs responsible for the bradycardia. He was afebrile with a capillary blood glucose of 118 mg/dL. Another finding from his physical examination was bradypnoea, with 10 to 13 breaths per minute despite an average oxygen saturation of 98%. There were no laboratorial abnormalities except for a serum alcohol concentration above 3 g/L.

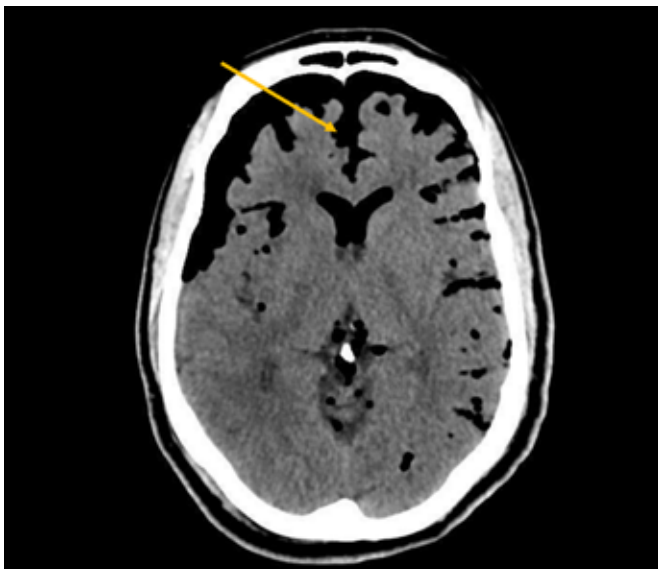


Figure 1. In this axial view, it is evident the separation of the frontal lobes at the interhemispheric fissure, outlining Mount Fuji sign (arrow) which is indicative of tension pneumocephalus.

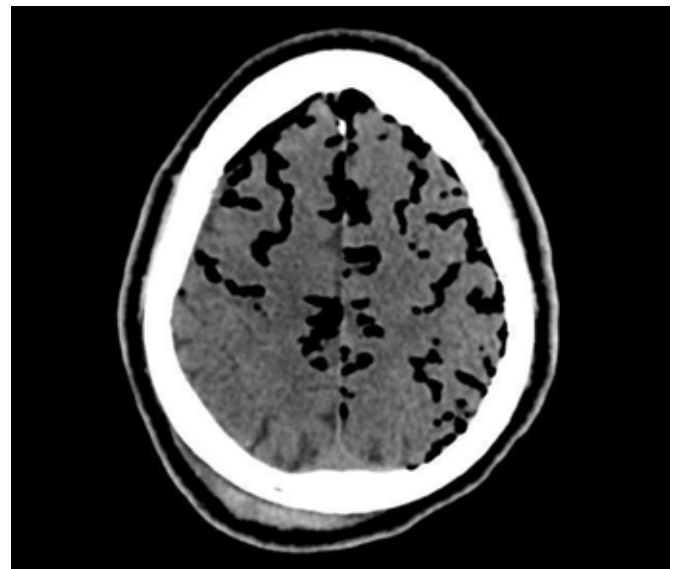


Figure 2. In this CT scan there are multiple small foci of air within the subarachnoid space which is called air bubble sign that also result from increased tension of air in the subdural space.

1. Department of Internal Medicine, Hospital de Cascais, Alcabideche, Portugal; Master's Degree in Medicine; Internal Medicine Resident. **2.** Department of Internal Medicine, Hospital de Cascais, Alcabideche, Portugal; National School of Public Health, Nova University Lisbon, Lisboa, Portugal; Public Health Research Centre, Universidade NOVA de Lisboa; *Comprehensive Health Research Centre - Universidade NOVA de Lisboa.*

Recebido/Received: 18/02/2021 - **Aceite/Accepted:** 24/02/2021 - **Publicado/Published:** 31/03/2021

© Author(s) (or their employer(s)) and Lusiadas Scientific Journal 2021. Re-use permitted under CC BY-NC. No commercial re-use. © Autor (es) (ou seu (s) empregador (es)) e Lusiadas Scientific Journal 2021. Reutilização permitida de acordo com CC BY-NC. Nenhuma reutilização comercial.

Computed tomography (CT) scan performed showed right hemotympanum as well as the presence of subdural air causing local compression of frontal and temporal lobes and multiple small air bubbles scattered through several cisterns (Figs 1 and 2) both suggestive of tension pneumocephalus. He was submitted to urgent craniotomy, repair of cerebrospinal fluid leak and antibiotic therapy, recovering consciousness without any sequelae.

Pneumocephalus is defined as the presence of intracranial air.¹ It is an uncommon complication of traumatic head injury, affecting 0.5%-1% of cases, especially when fractures of the skull base and middle ear cavity occur, traversing a sinus or mastoid air cells.^{2,3} In this case, although ethanolism was a confounding factor, the patient exhibited some clinical and radiological signs of raised intracranial pressure^{4,5} that demand urgent and life-saving decompression.

Responsabilidades Éticas

Conflitos de Interesse: Os autores declaram a inexistência de conflitos de interesse na realização do presente trabalho.

Fontes de Financiamento: Não existiram fontes externas de financiamento para a realização deste artigo.

Confidencialidade dos Dados: Os autores declaram ter seguido os protocolos da sua instituição acerca da publicação dos dados de doentes.

Consentimento: Consentimento do doente para publicação obtido.

Proveniência e Revisão por Pares: Não comissionado; revisão externa por pares.

Ethical Disclosures

Conflicts of Interest: The authors have no conflicts of interest to declare.

Financing Support: This work has not received any contribution, grant or scholarship.

Confidentiality of Data: The authors declare that they have followed the protocols of their work center on the publication of data from patients.

Patient Consent: Consent for publication was obtained.

Provenance and Peer Review: Not commissioned; externally peer reviewed.

ORCID iD: Filipa Taborda <https://orcid.org/0000-0002-9769-5579>

References

1. Pereira CU, Dezena RA, Meguins LC, Teixeira MP. Pneumocephalus. Review of Literature. *J Bras Neurocirurg.* 2015;26:47-56.
2. Cunqueiro A, Scheinfeld M.H. Causes of pneumocephalus and when to be concerned about it. *Emerg Radiol.* 2018;25:331-40.
3. Sharma A, Sharma NA, Sengar RL, Iyengar SN. Post traumatic pneumocephalus: A tertiary institute experience. *Global Journal Res Anal.* 2018;7:3.
4. Heidari SF. A Patient with massive pneumocephalus without sign of tension pneumocephalus. *J Intensive Crit Care.* 2016;2:3.
5. Clement AR, Palaniappan D, Panigrahi RK. Tension pneumocephalus. *Anesthesiology.* 2017;127:710.