

# A Case of Chronic Cavitary Pulmonary Aspergillosis

## Um Caso de Aspergilose Pulmonar Cavitária Crónica

Tatiana Oliveira <sup>1\*</sup>; Mariana Abreu Vieira<sup>1</sup>; Patrícia Cipriano<sup>1</sup>; Mafalda Guimarães<sup>2</sup>

### \*Corresponding Author/Autor Correspondente

Tatiana Oliveira [tattiana.pm.oliveira@gmail.com]

Hospital de Cascais Dr. José de Almeida, Av. Brigadeiro Victor Novais Gonçalves 2755-009, Alcabideche

ORCID: <https://orcid.org/0000-0002-0441-3713>

<https://doi.org/10.48687/lj.196>

**Keywords:** Pulmonary Aspergillosis/diagnosis; HIV Infections

**Palavras-chave:** Aspergilose Pulmonar/diagnóstico; Infecções por HIV

A 53-year-old man, with a history of poorly-controlled HIV-1 infection diagnosed 15 years ago, who abandoned antiretroviral (ARV) therapy 5 years ago, pulmonary and ganglionic tuberculosis treated 7 years ago and a past history of intravenous drugs abuse, presented to the emergency department with a three months history of dyspnea, cough, hemoptysis, weight loss (63% total body weight) and asthenia.

At admission he was febrile 38°C, normotensive but tachycardic and with peripheric oxygen saturation of 98%. He was cachectic (IMC 15.6 kg/m<sup>2</sup>) and presented bilateral rhonchi. Blood tests revealed anemia (hemoglobin 11.1 g/dL), thrombocytopenia (platelets 131 x10<sup>9</sup>/L), elevation of C-reactive protein (4.46 mg/dL) and erythrocyte sedimentation rate (80 mm/h). CD4+ cell count was 134/uL and HIV viral load was 9769 copies/mL. Chest radiograph showed a nodule in the right upper lobe (Fig. 1) and computed tomography (CT) thorax scan revealed a mass inside a large cavitation with 40x42 mm and multiple areas of consolidation in the medium lobe and lower lobes (Figs. 2, 3 and 4).

Due to suspicion of *Aspergillus* spp. disease, specific IgG for *Aspergillus fumigatus* and serum galactomannan *Aspergillus* antigen were tested, and the patient was started on voriconazole.

*A. fumigatus* IgG was positive after 3 days; mycology culture of sputum identified *A. fumigatus* after 15 days. Serum galactomannan *Aspergillus* was also positive. Additionally, *Haemophilus influenzae* was identified on sputum culture, suggesting a superinfection, and ampicillin was initiated. Bacilloscopy, blood and sputum culture in Löwenstein–Jensen medium and aerobic and anaerobic blood cultures were negative. Symptoms improved substantially after initiation of both medications. Aminocaproic acid was needed to control hemoptysis. Patient restarted ARV with tenofovir alafenamide/ emtricitabine + dolutegravir 8 days after admission. He was considered for surgery and was discharged 26 days after admission awaiting procedure. Patient returned to the HIV clinic maintaining adherence to treatment and achieving recovery of CD4+ and undetectable viral load. He was submitted to right superior lobectomy 6 months after discharge and continued voriconazole for 11 months. There was no relapse.

Chronic cavitary pulmonary aspergillosis (CCPA) is the classic form of chronic pulmonary aspergillosis.<sup>1</sup> Radiologically, it typically presents with a cavitary lung lesion with surrounding inflammation, with continued destruction of adjacent lung tissue. Symptoms include cough, chest pain, hemoptysis, dyspnea, weight loss, night sweats and tiredness, and constitutes

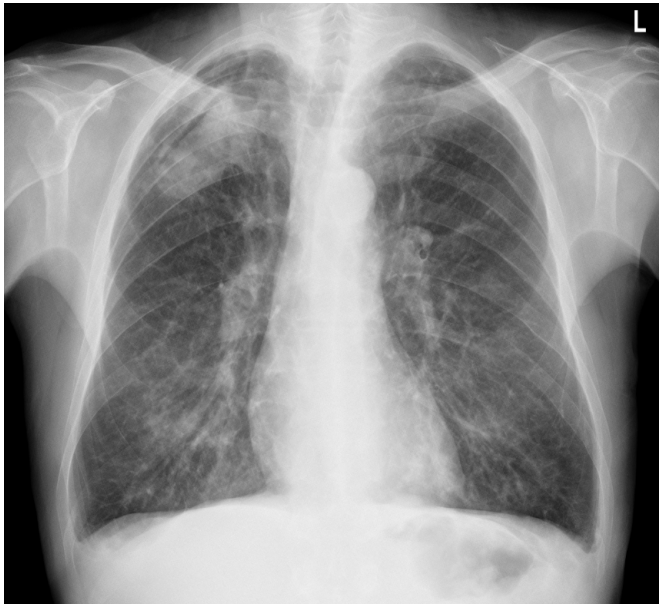**1.** Internal Medicine Unit, Department of Medicine, Cascais Hospital Dr. José de Almeida, Cascais, Portugal. **2.** HIV-AIDS Functional Unit, Cascais Hospital Dr. José de Almeida, Cascais, Portugal

**Recebido/Received:** 15/12/2023 – **Aceite/Accepted:** 27/02/2024 – **Publicado online/Published online:** 04/03/2024 – **Publicado / Published:** 28/06/2024

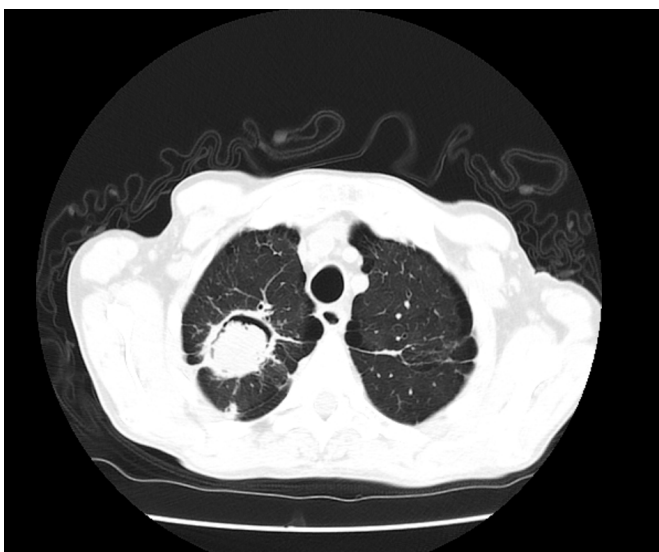
© Author(s) (or their employer(s)) and Lusíadas Scientific Journal 2024. Re-use permitted under CC BY-NC 4.0. No commercial re-use.

© Autor (es) (ou seu (s) empregador (es)) e Lusíadas Scientific Journal 2024. Reutilização permitida de acordo com CC BY-NC 4.0. Nenhuma reutilização comercial.

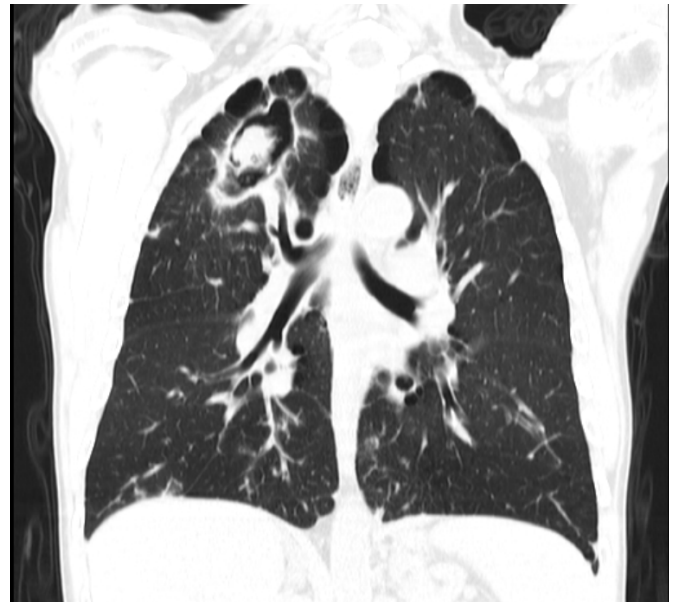differential diagnosis with tuberculosis.<sup>1,2</sup> Diagnosis requires 3 conditions: persistent symptoms for 3 months at least, radiological findings compatible with aspergillosis for 3 months at least and direct evidence of *Aspergillus* infection, that can be on culture from biopsy or in the presence of IgG for *Aspergillus*, after exclusion of alternative diagnosis.<sup>2</sup> A culture from sputum or bronchoalveolar lavage does not contribute to the diagnosis as it may be related to colonization.<sup>1,2</sup> First line treatment is voriconazole or isitraconazole<sup>3</sup> for a minimum of 6 months in patients with local and systemic symptoms or with progressive loss of lung function. Lung resection should be considerate, especially in patients with hemoptysis.<sup>2,4</sup> Without treatment, mortality rate is higher than 50% within the first year, however with prompt treatment, prognosis improves significantly.<sup>5</sup>



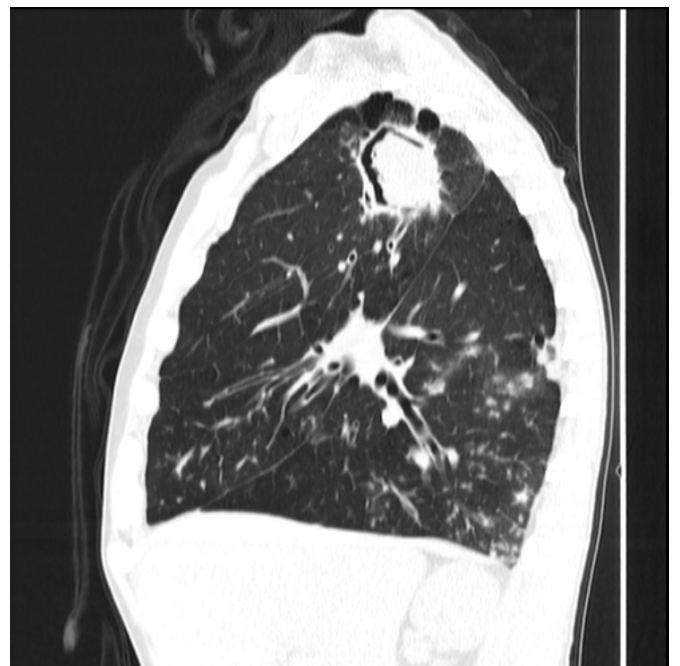**Figure 1.** Nodule in upper right lobe on thorax radiography



**Figure 2.** A mass (mycetoma) inside a cavity in coronal plane on CT thorax scan



**Figure 3.** A mass (mycetoma) inside a cavity in sagittal plane on CT thorax scan



**Figure 4.** A mass (mycetoma) inside a cavity in axial plane on CT thorax scan

### Responsabilidades Éticas

**Conflitos de Interesse:** Os autores declaram a inexistência de conflitos de interesse na realização do presente trabalho.

**Fontes de Financiamento:** Não existiram fontes externas de financiamento para a realização deste artigo.

**Confidencialidade dos Dados:** Os autores declaram ter seguido os protocolos da sua instituição acerca da publicação dos dados de doentes.

**Consentimento:** Consentimento do doente para publicação obtido.

**Proveniência e Revisão por Pares:** Não comissionado; revisão externa por pares.

## Ethical Disclosures

**Conflicts of Interest:** The authors have no conflicts of interest to declare.

**Financing Support:** This work has not received any contribution, grant or scholarship.

**Confidentiality of Data:** The authors declare that they have followed the protocols of their work center on the publication of data from patients.

**Patient Consent:** Consent for publication was obtained.

**Provenance and Peer Review:** Not commissioned; externally peer reviewed.

## Contributorship Statement

**TO, MV, PC, MG:** Escrita do Artigo e aprovação da versão final a ser publicada

## Declaração de Contribuição

**TO, MV, PC, MG:** Article writing and approval of the final version to be published

## References

1. Kosmidis C. Chronic pulmonar aspergillosis: Epidemiology, clinical manifestations and diagnosis. Uptodate. 2023. [cited 2023 Dec 3] Available from: [https://www.uptodate.com/contents/chronic-pulmonary-aspergillosis-epidemiology-clinical-manifestations-and-diagnosis?search=aspergillosis&source=search\\_result&selectedTitle=3~150&usage\\_type=default&display\\_rank=3](https://www.uptodate.com/contents/chronic-pulmonary-aspergillosis-epidemiology-clinical-manifestations-and-diagnosis?search=aspergillosis&source=search_result&selectedTitle=3~150&usage_type=default&display_rank=3)
2. Ullmann AJ, Aguado JM, Arian-Akdagli S, Denning DW, Groll AH, Lagrou K, et al. Diagnosis and management of Aspergillus diseases: executive summary of the 2017 ESCMID-ECMM-ERS guideline. *Clin Microbiol Infect.* 2018;24:e1-e38. doi: 10.1016/j.cmi.2018.01.002.
3. Zarif A, Thomas A, Vayro A. Chronic Pulmonary Aspergillosis: A Brief Review. *Yale J Biol Med.* 2021 Dec 29;94(4):673-679.
4. Patterson TF, Thompson GR 3rd, Denning DW, Fishman JA, Hadley S, Herbrecht R, et al. Practice Guidelines for the Diagnosis and Management of Aspergillosis: 2016 Update by the Infectious Diseases Society of America. *Clin Infect Dis.* 2016;63:e1-e60. doi: 10.1093/cid/ciw326.
5. Cadena J, Thompson GR 3rd, Patterson TF. Aspergillosis: epidemiology, diagnosis, and treatment. *Infect Dis Clin North Am.* 2021;35:415-34. doi: 10.1016/j.idc.2021.03.008.